Positional Release Technique

A valid technique for use by Physical Therapy Practitioners?

Stephen Fallon MIAPT
Registered Physical Therapist

Margaret Walsh (BSc.) MIAPT
Registered Physical Therapist

IPTAS
Conference 2012

Contents

Abstract

Positional Release Technique
Is this a valid technique for use by the Physical Therapist?

The aim of this presentation is to provide evidence to open the mind of the therapist who may be stuck in the mindset/habit of forced change (Direct Technique e.g. Deep Soft Tissue Work).

While a direct approach is beneficial a more gentle technique (Indirect Technique i.e. Positional Release Technique, Strain Counter strain) is available and not so stressful on the Therapist or the Patient. Given the hand intensive work of the Physical Therapist is it possible that this more gentle approach can achieve good result for the patient while reducing the stress on the therapist?

We will provide a history to the development of indirect technique, explain the physiology and principles underlying the technique with evidence from various books, Journals and 4 case studies.

This poster presentation will be followed by a demonstration of Positional Release Technique.

Stephen Fallon MIAPT
Registered Physical Therapist

Margaret Walsh (Bsc.) MIAPT
Registered Physical Therapist

Theoretical Model

Korr's model of the Facilitated segment *fig. 1*

"A lesion represents a facilitated segment of the spinal cord maintained in that state by impulses of endognenous origin entering the corresponding dorsal root. All structures receiving efferent nerve fibres from that segment are, therefore, potentially exposed to excitation or inhibition." (Denslow & Korr as cited in D'Ambrogio & Roth 1997)

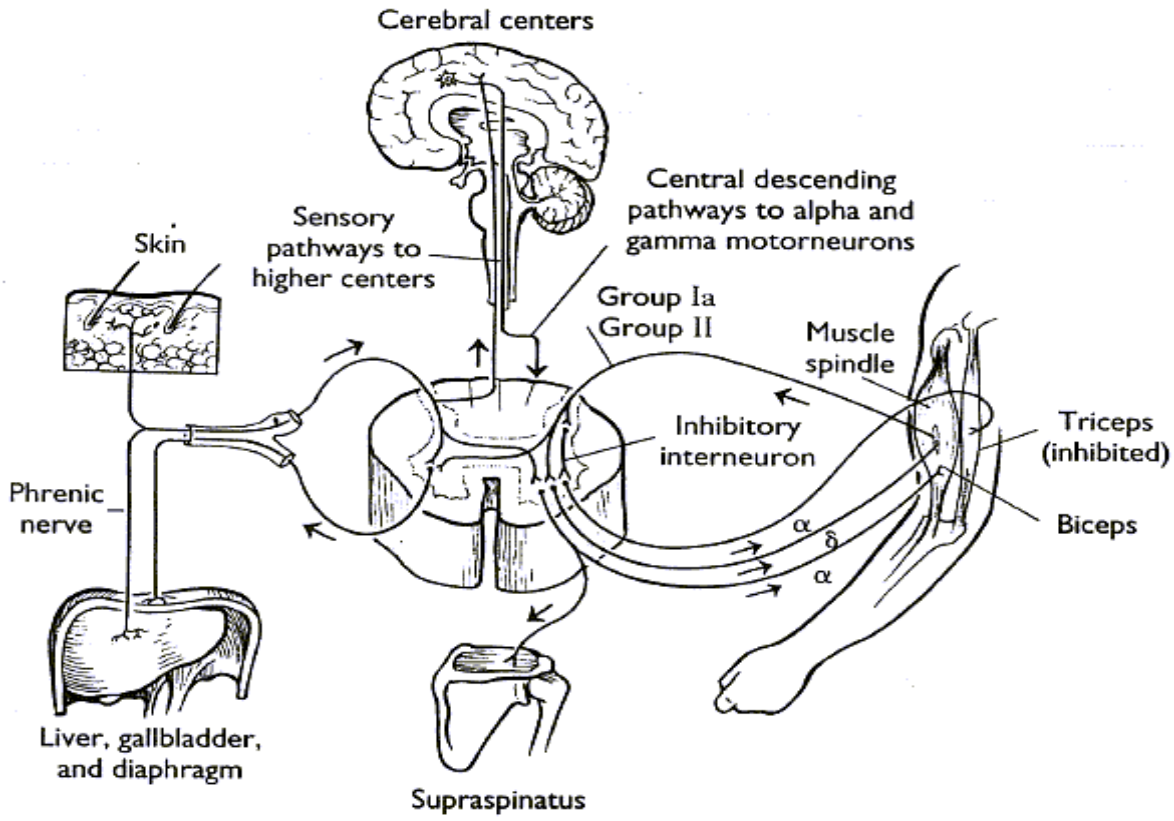

Fig. 1 Facilitated segment components C5-7 (*adapted from D'Ambrogio & Roth 1997)*

Under homeostasis efferent neurons are insulated and require a convergence of impulses to fire. In a facilitated segment the constant barrage of abnormal impulses converging on the anterior horn cells weakens the insulation keeping the segment in a state of constant excitation. Stimuli that would be ineffectual under homeostatic conditions now cause neuronal firing to all muscles and organs receiving innervations from the facilitated segment(s) (Deig 2006)

Janda (as cited in Deig 2006) identified muscle imbalance patterns of postural muscles that tend to become hypertonic through facilitation and dynamic muscles that become hypotonic through inhibition as responses to abnormal afferent input.

Neuromuscular Feedback
Proprioceptors monitors of the musculoskeletal system

Ruffini Receptors

Location	Joint capsule
Role	Information on position, velocity & direction of motion transmitted to cerebellum & cerebral cortex No direct influence at segmental level. (D'Ambrogio & Roth 1997)

Golgi Tendon Organs

Location	Musculotendinous Junction
Role	Respond to excessive load & tension on the muscle Impulses have an inhibitory effect at the spinal level Protection from over stretch. (D'Ambrogio & Roth 1997)

Muscle Spindles

Location	Between the fibres of striated muscle
Role	Respond to changes in position, load & velocity of body parts connected directly & indirectly to the spinal segment via gamma & alpha neurons. Most sensitive proprioceptor

Responsible for maintaining a resting tone (gamma bias) ensuring the ability of the muscle(s) to respond to changing demands. This may also be a mechanism for the development & perpetuation of the response to myofascial injury. (D'Ambrogio & Roth 1997)

Jones (as cited in D'Ambrogio & Roth 1997) suggests the muscle spindle has an important part to play in somatic dysfunction and that dysfunction occurs not because of the original strain but as a result of the response to the strain. The antagonist muscle goes from minimal afferent input at the time of strain to maximal afferent input as a result of quick movement away from the strain *(fig2.)* The antagonist now reports that it is strained even though it is shorter than its normal resting length. This incorrect proprioceptive information is thought to continue as neuromuscular dysfunction.

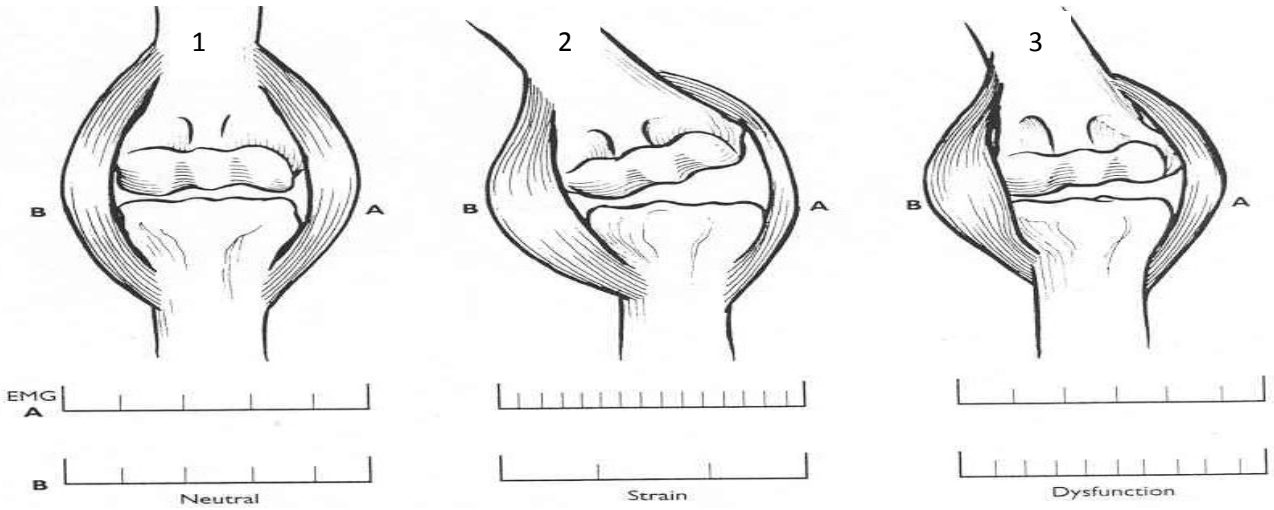

Fig. 2 *Jones neuromuscular model (Adapted from* D'Ambrogio & Roth 1997)

Van Buskirk (as cited in Deig 2006) suggests, should the non neutral joint position be maintained the dysfunction will progress from acute to chronic as indicated by connective tissue reorganisation. In that, the tissue becomes more random in the shortened muscle and less able to take stress, while elongating in the lengthened muscle. The joint can stay in the non neutral position without constant muscular contraction. However, any stress or motion counter to the original shortening will reactivate the nociceptive cycle.

Van Buskirk & Schmidt (as cited in D'Ambrogio & Roth 1997) state that nociceptors are known to produce muscle guarding and should be considered as having possible involvement in the perpetuation of irritable reflexes connected with somatic dysfunction.

Korr (as cited in Deig 2006) should the faulty proprioceptive signals continue greater muscle contraction can continue. The disparity in intrafusal / extrafusal fibres increases afferent input stimulating the extrafusal fibres to contract more in an attempt to calm the spindle.

This increase in the amplitude of impulses from proprioceptors and nociceptors routed to a particular segment overloads the normal pathway causing an electrochemical overflow. The overflow can travel ipsilaterally, contralaterally or vertically (D'Ambrogio & Roth 1997)

These impulses can arise from any tissue causing the CNS to misinterpret the information due to electrochemical overflow in the involved segment. E.g. gallbladder pain manifested as shoulder pain. This overload of the CNS is referred to as a Facilitated Segment

Due to this excessive discharge coming from numerous receptors the facilitated segment may eventually become self-perpetuating source of irritation itself (D'Ambrogio & Roth 1997).

Weiselfish (1993) (as cited in D'Ambrogio & Roth 1997) found Positional Release Therapy (PRT) seemed to have a calming effect on the level of excitability within the facilitated segment.

Evidence to support clinical use

Several studies investigating Strain Counter Strain (SCS) report decreased pain or palpation tenderness. The first randomized control study had subjects with hip TPs receive SCS, exercise, or SCS and exercise. While treatment decreased pain for all subjects, those receiving SCS demonstrated significantly larger decreases than those receiving exercise alone (Wong and Schauer, 2004). Groups receiving SCS had medium effect sizes but conclusions must be drawn with caution because the study lacked blinding, sham positioning, standardized palpation pressure, or patients with clinical pathology, it also noted that the Jones method of TP pain assessment was found to be only weakly reliable and a valid tool for assessing pain levels, therefore clinicians should be cautioned from drawing conclusions based on findings using the TPPS (Wong and Schauer, 2004).

(Pedowitz 2005) carried out a trial on use of SCS on iliotibial band friction syndrome and found that the use of SCS as a treatment modality the athlete can experience reductions in pain and be capable of returning to full activity in less than three weeks from initiation of treatment, this time the case compares to an average of 4-6 weeks of conventional therapy.

A case report carried out by (Collins 2007) describes the examination, intervention, and outcomes for a patient with Complex Regional Pain Syndrome I (CRPS I) treated with Strain Counterstrain (SCS). The patient was diagnosed with CRPS I following a Grade II ankle sprain. Treatment consisted of SCS once per week for six months with one additional session each week in Months 4 through 6 for strengthening, endurance, and gait training.

A re-examination was performed monthly. A clinically significant decrease of 2 points in overall pain as measured with a numeric pain rating scale (NPRS) occurred as of Month 2; a 2-point decrease in tenderness on 10 of 13 SCS tender points also measured with an NPRS was documented as early as Month 1. Throughout the treatment period, an increase in function was noted by way of patient report and objective tests and measures. Gait improved with regard to cadence, use of an assistive device, and weight-bearing status. Single limb stance on the involved leg increased from 0 (s) to 40 (s) over the course of treatment and ankle active range of motion as measured with a goniometer and muscle strength as measured with manual muscle tests both returned to normal values. CRPS I remains a poorly understood and difficult-to-treat chronic syndrome. By way of its proposed effects on the neuromuscular system and facilitated segments, SCS may be an additional effective treatment tool in the management of some patients diagnosed with CRPS I.

A Randomized, blinded, sham controlled study was carried out by (Wong 2011) to determine the effect of strain counterstrain (SCS) techniques on forearm pronation and supination muscle strength compared to passive sham positioning. This was done using 12 healthy right-handed subjects (4 men, 8 women) with 19 included forearms (6 right, 13 left). Each forearm was individually and randomly assigned to the SCS or control group (9 SCS, 10 control).The method used involved subjects attending 3 sessions within 3 weeks.

Initial forearm pronation and supination strength was assessed at the first session. Forearm muscle strength was assessed in a stable seated position using a hydraulic dynamometer with doorknob-shaped handle. Pre- and post-treatment strength was assessed during the second session, with the SCS group receiving 1 SCS treatment to the pronator and supinator muscles and the control group receiving passive sham positioning between assessments. The third session consisted of 1-week follow-up forearm strength. Results showed that Results at baseline, the SCS and control groups were comparable with respect to age, gender, height, weight, hand dominance, and initial pronator

and supinator strength ($p > 0.05$). After treatment, control group strength remained unchanged ($p > 0.05$) while the SCS group increased pronation strength by 8.3% ($p = 0.009$) and supination strength by 11.9% ($p = 0.046$) from pre-treatment to follow-up 1 week later. SCS group strength increased more compared to the control group for pronation ($p = 0.045$) and supination ($p = 0.059$). This concluded that forearm strength increased after SCS in a healthy population with muscle tenderness, with greater strength increase apparent than after passive sham positioning.

Weiselfish (1993) (as cited in D'Ambrogio & Roth 1997) found PRT effective in treating severe neurological patients. PRT seemed to have a calming effect on the level of excitability within the facilitated segment.

Van Buskirk (1990) (D'Ambrogio & Roth 1997) PRT seem to have an influence in decreasing the threshold in the facilitated segment and provide the CNS with an opportunity to normalise neural activity.

Studies that support the effectiveness of PRT

Wong & Schauer-Alverez (2004) (as cited in Deig 2006) found that strain counterstrain on hip tender points and hip joint muscles decreased pain and dysfunction and increased the strength of weak hip muscles

Lewis & Flynn (2001) (as cited in Deig 2006) improvements were found in four case studies of pain and disability. A significant reduction in symptoms was reported through the use of PRT.

Effects of Positional Release Therapy

Normalisation of muscle hypertonicity
Clinically it has been found PRT appears to affect inappropriate proprioceptive activity helping to reset normal tone and resting length D'Ambrogio & Roth (1997)

Normalisation of fascial tension
After approximately 3 minutes PRT begins to engage the fascial tension patterns associated with trauma, inflammation and adhesive pathology Weiselfish (1993) (as cited in D'Ambrogio & Roth 1997).

Reduction of joint hypomobility
When muscle tension is normalised this appears to ease the tension around the joint. Proper biomechanical movement is restored (D'Ambrogio & Roth (1997).

Increased circulation & decreased swelling
Rathburn & Macnab (1970) (as cited in Chaitow 2007) *performed studies on cadavers by injecting radiopaque dye into muscles. They found when a muscle was in a position of ease the dye was more likely to spread into the vessels than when a muscle was in a neutral position. With increased circulation comes improved healing improved lymph flow and decreased swelling.*

Decreased pain
D'Ambrogio & Roth (1997) *suggest the pain of joint dysfunction is position orientated, from severe pain in one position to ease in another position. Pain may also be connected with guarded muscles and fascial tension. PRT appears to ease this guarding in turn easing pain.*

Increased strength
As proprioception is normalised and a neural balance occurs, inhibition causing pain is removed, normal tone and function are restored (D'Ambrogio & Roth (1997).

Possible benefits for the patient

Change is not forced upon the tissue as with deep myofascial work

Acute spasms can be eased in a gentle manner

Balance to joint restriction due to muscle guarding

Improved range of motion

Given the continuous nature of the fascial web an easing of tension in one area could in theory allow easing of tension elsewhere improving postural alignment

Provides an improved environment for healing to occur

Calming of the facilitated segment helping to normalise neural signalling

Possible benefits for the therapist

Given the manual specificity of body work and its repetitive nature the opportunity for cumulative trauma disorders to develop is a concern. Any chance of achieving positive outcomes for the patient while placing less pressure on the therapist is beneficial for both and therapist longevity.

PRT would seem to offer the therapist a more gentle approach affording greater opportunity to help the acute patient.

Conclusions

According to some evidence PRT does seem theoretically to be a valid technique although other evidence suggests to the contrary and that further research needs to be carried out. In comparing this to myofascial work the evidence also suggest further research needs to be undertaken yet therapists use myofascial work on a daily basis and their patients reap the rewards. Of course research will always open the door to further discussion and debate this is after all the cycle of enquiry.

Our primary role as Physical Therapists it to take care of our patient's musculoskeletal health. Surely a technique which places less stress on the patient and the therapist is beneficial to both parties? Should we really have to force change on the musculoskeletal system through deep myofascial work to achieve a goal? Are we not overlooking the body's own ability to heal? This gentle technique of PRT has the ability to place the body in a position which encourages a natural healing environment. This was demonstrated by Rathburn & Macnab (1970) (as cited in Chaitow 2007) they found that when tissues were place in a position of ease an increase in circulation occurred.

Korr's facilitated segment model has been around for many years with evidence for and against. Perhaps there is an opportunity here for further research into this model and resultant technique? Do we really need to force change on the human body, is it that stubborn or do we just need to change a direct mindset to an indirect one?

Reference list

Chaitow, L. (2007) *Positional Release Techniques,* Philadelphia, Churchill Livingstone Elsevier

Collins CK. Physical therapy management of complex regional pain syndrome in a 14-year-old patient using strain counterstrain: a case report. Journal of Manual and Manipulative Therapy 2007; 15(1):25e41.

D'Ambrogio, K. J., Roth, G. B. (1997) *Positional Release Therapy,* Missouri, Mosby

Deig, D. K. (2006) *Positional Release Technique from a dynamic system perspective, Indianapolis,* Somatic Publications

Pedowitz RN. Use of osteopathic manipulative treatment for iliotibial band friction syndrome. Journal of the American Osteopathic Association 2005; 105(12):563e7.

Wong CK, Schauer CS. Reliability, validity, and effectiveness of strain counterstrain techniques. Journal of Manual and Manipulative Therapy 2004; 12(2):107e12.

Wong CK, Moskowitz N, Fabillar R. Effect of strain counterstrain on for forearm strength compared to placebo positioning. International Journal of Osteopathic Medicine, in press. Available online 21 January 2011: doi:10.1016/j.ijosm.2010.11.004770

Appendix 1

CASE STUDY 1 S.Fallon MIAPT
Acute Back Spasm

Patient History
56 year old male, good general health no previous musculoskeletal issues. Bent over to lift 6 month old daughter out of cot, felt grabbing pain in right lower back as he lifted his daughter up. Pain increased that evening accompanied by stiffness in the left and right lower back and anterior right hip region. Had difficulty in getting to sleep that night, took 2 neurofen plus, this eased the pain stiffness remained.
That morning he had manually moved 30 bales of straw from one trailer to another by himself due to his tractor being serviced. He did note that his back was a bit stiff after the work. It was shortly after this when he lifted his daughter from the cot.
Presented to clinic two days post injury on instruction from doctor. NSAID were prescribed, these caused stomach upset, only one 50mg Cataflam had been taken the day post injury and none since then.

Subjective Findings
Main complaint – grabbing lower back pain (5/10) on right going from seated to standing. Stiffness across lower back makes straightening up difficult. Also has pain (4/10) over the right superior anterior thigh, patient indicates right ASIS region. This can get worse when he drives his car for more than 15 minutes "feels like it gets tighter".
Using heat on his lower back in the evening for about 30 minutes helps to ease his discomfort and eases the motion of going from sitting to standing.

Objective findings (*positives reported)*
Patient presented with a slightly flexed lumbar posture and a slightly flexed right hip posture.
Neurological screen was clear confirming the patient's doctor's findings.
Range of motion testing showed patient had difficulty extending from a flexed position due to stiffness. Full lower back extension (active) was moderately decreased by a grabbing pain (5/10) in the right lower back. Lateral flexion to the right (active) moderately decreased by a grabbing pain (5/10) in the right lower back. Right hip extension (active) moderately decreased by pain (4/10) across the lower back, stiffness was also reported in the right ASIS region. 'Thomas Test' was positive.

Treatment Goals
Reduce acuteness of symptoms, restore normal range of motion, educate in lower back care exercise and return to normal functional activities of daily living.

Treatment & Response
Treatment 1
Positional release applied to right psoas, patient reported warm sensation in lower back and an easing of stiffness in hip region. Reassessment showed improvement in hip extension and lessening of discomfort (2/10)across lower back.
Dry needling applied to L2 and L4 right paraspinal region. Reassessment showed improvement in lower back extension with grabbing pain reduced to (3/10). Patient instructed in the use of self release for Psoas.

Treatment 2 (4 days later)
Patient reports good decrease in pain and an improvement in mobility. Grabbing pain is at (2/10) and not as frequent. Lower back extension(active) from flexion is pain free to end of range where grabbing pain is reported (3/10) right lower back. Lateral flexion to the right (active) slightly decreased by a grabbing pain (3/10) in the right lower back. Right hip extension (active) slightly decreased by pain (2/10) across the lower back.
Positional release applied to right Psoas, right quadratus lumborum. Mobilisation to right hip. Dry needling applied to L2 and L4 bilateral paraspinal region.
Reassessment showed hip extension to be full and pain free, lower back extension to end of range pain (2/10) right lower back. Lateral flexion to the right to end of range pain (1/10) right lower back.
Patient instructed in the use of core stability exercise and self release for Psoas and quadratus lumborum.

Treatment 3 (7 days later)
Patient reports a good initial decrease in pain. 3 days post treatment he had no choice but to help a cow calf. His right lower back was stiff and sore later that day. Self release was performed on Psoas which did ease the

soreness on the third attempt. Reassessment showed right hip extension (active) to be slight decrease and causing pain (3/10) in the right lower back. Right hip internal rotation (active) to end of range pain (2/10) right gluteal region.
PRT performed to right Psoas, Piriformis and Quadratus Lumborum. On releasing Piriformis the patient reported a feeling of warmth in the right lower back. Dry needling applied to L2 and L4 bilateral paraspinal region and to Piriformis.
Range of motion was normal post treatment no pain reported. Patient instructed in self release for piriformis and a review of core stability exercise was carried out.

Treatment 4 (10 days later)
Patient has no symptoms to report. Reassessment was clear. Further core stability exercises were introduced. Patient was rescheduled for 6 weeks for a Reassessment of core stability.

6 Weeks later the patient was reassessed and showed an improvement in core stability with no symptoms to report. The patient had also enrolled in a Stott Pilates class. Patient was discharged.

On reflection PRT certainly had a role to play in the patient's recovery and at times it was evident to see the patient relax as the techniques were performed. The Dry Needling of strategic points also had a role to play in calming the muscle spasm. The patient too was also very diligent at carrying out the home exercise plan and self release techniques.

CASE STUDY 2 S. Fallon MIAPT
Chronic Frontal Headaches

Patient History
38 year old female accountant works 30 hours per week, good health. Only previous trauma at 22 years old fell backwards off a 4 foot garden wall and landed on upper back and neck. Pain was felt a couple of days after in the posterior neck (3/10). Had several physio sessions which eased the problem. Since then neck can get stiff now and then, patient puts it down to poor posture.
Over a 10 week period patient has had worsening frontal headaches initially more prevalent towards the end of the week. From initial onset to week 3 headaches were present most of the time. Paracetamol did ease but not completely. Weekends were really the only time the headache seemed to go. By week 6 patient had gone to a friend who is a doctor. Patient was sent for a CT scan, no abnormalities were detected, blood pressure was normal. Doctor prescribed Solpadine and suggested patient do some light exercise and have a few massages.
By week 9 patient had received 3 massages and used the Solpadine only once a day for 2 weeks. Headaches had ease to a more manageable level but workload was increasing and patient did not want to rely on Solpadine to manage the pain. Returned to doctor who advised Physical Therapy.

Subjective Findings
Patient presented in week 10 from onset. Patient reports and increase in workload due to time of year and some staff have been let go. Initially headaches started towards the end of the week in the forehead region, "fuzziness pain" (1-2/10). As the weeks went on she noticed that the pain was more "vice like" (3-5/10) and it was affecting her ability to work. She is aware that her desk set up is "not great" and works mostly on a laptop as she brings it home with her in case she needs to work at home. Which recently she has had to do and hour or so to stay on top of her work.
Patient reports that the headaches may be getting worse again, they had eased after massage but never really gone and she wants to stop taking Solpadine.

Objective findings (*positives reported)*
Significant forward head posture, rounded right shoulder girdle. Neck flexion (active) was moderately decreased with tightness reported (3/10) in the posterior neck and upper thoracic spine. Lateral flexion to the left was moderately decreased with tightness reported (4/10) in the right upper Trapezius. Pain was also reported (3/10) over the right eyebrow region. Palpation of the posterior neck from C4 upwards evoked pain at the site (3/10). Palpation of the suboccipital region recreated the patient's headache symptoms pain (5/10)
Addson Test was positive on the right.

Treatment Goals
Normalise range of motion, reduce muscle tension, decrease pain. Educate patient regarding good postural habits and ergonomics. Put in place a home exercise plan.

Treatment & Response

Treatment 1
Inhibition to upper Trapezius left followed PRT to the right upper Trapezius. Neck Lateral flexion to the left increased, tightness (2/10) but referred pain was still present. Dry needling to right upper Trapezius decrease referred pain to (2/10). PRT was applied to the suboccipital region which caused mild spasming of the right Sternocleidomastoid muscle, which only lasted a few seconds. Patient also reported mild discomfort (2/10) in their forehead during the positioning.
Patient was educated regarding good ergonomics and was given a self release for the Sub Occipitals.

Treatment 2 (6 days later)
Patient reports that headache was bad (6/10) the evening after the treatment but overall feels there was an improvement in the severity (3-4/10) of the headaches and not as vice like. Has ordered a stand to raise her laptop in work as well as a full ergonomic keyboard and mouse. Did not get much time to do self release.

Reassessment showed postural findings the same. Neck flexion (active) was moderately decreased with tightness reported (2/10) in upper thoracic spine. Lateral flexion to the left was slightly decreased with tightness reported (3/10) in the right upper Trapezius. Pain was also reported (2/10) over the right eyebrow region. Palpation of the posterior neck C4 upwards evoked pain at the site (3/10). Palpation of the suboccipital region recreated the patient's headache symptoms pain (4/10). Addson Test was positive on the right.
A similar treatment to the first was carried out. This session also involved PRT to posterior cervical region, Scalenes right, right upper Trapezius, Pectoralis Major right. Mobilisation to cervical spine and right shoulder girdle. Patient reported feeling a "clunk" in her head during the Sub Occipital release.
Neck flexion (active) was to end of range. Lateral flexion to the left was to end of range with slight tightness (1/10) reported and no referred pain. Patient was educated in good postural habits and self release for Sub Occipital region was reinforced.

Treatment 3 (7 days later)
Patient reports feeling great for the first part of the week with only very minor headaches (1-2/10) towards the end of the day. By the end of the week headaches was stronger (2-3/10) but manageable. Patient reports being more tuned into her poor postural habits also found time to do self release.

Reassessment showed Neck flexion (active) was to end of range with tightness reported (2/10) in posterior neck. Palpation of the posterior neck C4 upwards evoked pain at the site (1/10). Palpation of the suboccipital region recreated the patient's headache symptoms pain (2/10).
Treatment as previous and also included mobilisations to the upper thoracic spine.
Reassessment palpation of posterior neck was slightly tender (1/10) ranges of motion normal. Home care reinforced.

Treatment 4-6
Over the following two weeks were as above with improvements in patients symptoms each week.

Treatment 7
3 weeks after treatment 6, patient reports feeling great and less stressed. Posture had improved and no headaches were reported. Reassessment showed some slight tenderness in the posterior neck (1/10) on palpation. Similar treatment to previous sessions carried out. Patient was discharged.

Reflecting on this case the patient was very stressed about the headaches, job security and there was intimation that family life was stressful. Given the stress factors involved it was a concern if these were not controlled the headaches may persist despite my best efforts as a therapist. However, it did seem after the patient found relief from the treatment they found it possible to deal with all other stressors in their life. Positional Release certainly seemed to have worked in this case.

Case Study 3 M. Walsh BSc. MIAPT

Female, 37 year old housewife presented with pain in the sacral region localised along the right medial buttocks. Her pain had presented itself while she was pregnant, at the latter stage of her pregnancy, she was now 13 months post pregnancy and the pain has not subsided. She felt it was staying the same if not slightly worse, she marked it a 5/10, she also associated a diffuse lumber ache that has started in the last 3-4 months, and it is aggravated with prolonged standing or walking. She has been to get G.P who advised her to get Physiotherapy; she has been following a strength and flexibility programme for the last 6 weeks with not relief at all.

Findings

- All Lumber tests were normal, with full ROM,
- All neurological testing was also negative.
- Resisted hip flexion was slightly weaker than the left side and caused slight discomfort. (2-3)
- Passive hip extension also caused slight discomfort. (1-2)

Goals

As the findings were quiet vague and the client had being doing a prescribed rehabilitation programme, The main goal was to use alternative techniques to try and see if there was any marked improvement, treatments that had not been used previously.

Treatment and response

The first treatment carried out was some massage with movement to the sacral region and trigger point release to the gluteus medius muscle, the client was then reassessed with no change and again assessed 48 hours later again with no change

Treatment two 3 days

This time the focus was on the iliacus muscle, a position and release technique was used to first find the area of aberrant tone and then following procedure. The patient reported a feeling of ease when both hips where flexed to 90 degrees and the knees are allowed to flop outward, creating external rotation of the femurs. The client was then assessed after treatment and reported the pain in her sacral region had decreased from a 5 to a 2. 48 hours later the client was assessed again, and reported that the pain level was still decreased between a 2-3.

Treatment three 3days

The same procedure was followed again, with the same results, this time the client could not feel hardly any symptoms immediately after treatment. A home care stretch was given for the iliopoas muscle , to be carried out 3 times a day. The client was then assessed 48 hours later and reported that she was feeling at a level 2, with the frequency less, she was encouraged to carry out her normal activities.

Treatment four 7 days

On assessment the client reported that the pain had stayed at a 2, and that she was not as aware of it as much, she had also started doing some light walking daily and reported no increased in the pain. The same treatment was completed, and after reassessment the client reported that she could

not feel any pain. The client was encouraged to restart her strength and flexibility programme that she had been prescribed previously.

Treatment five 2 weeks

On assessment, improved ROM in the hip, and increases core strength, the client had resumed all normal activities and was walking for 30 mins every second day with no ill effects.

Conclusion

When the patient presented with her symptoms, the patient had tried most forms of treatment, she was carrying out a strength and flexibility programme, and had been getting some soft tissue work on her lower back but to no avail. She was adamant that she did not want me to carry out the same treatment that she had been receiving and felt that the ache was deeper in her sacral region. As my assessment findings was very vague, I more so concentrated on my palpation skills and found the tender areas along the iliacus muscle, this I knew would tie in with her symptoms, and upon using strain counter strain she felt immediate relief. The effect was immediate and the relief lasted after each treatment, concluding that strain counter strain had a positive effect on the patient.

Case Study 4 M. Walsh BSc. MIAPT

Male 23 year old professional jockey presents with right groin pain with medial thigh pain that travels to the knee.(3/6) He noticed the pain was a gradual onset that began 3 months previous. The pain was made worse on twisting and turning and also after riding the horse for training sessions that could take up to 3 hours. He noted that the pain is getting worse since the original onset. He describes the pain as a sharp pain on twisting turning, and a deep ache on the other aggravating factors. He has not found any relieving factors but says it may be slightly less when he is not working. He does not remember any mechanism of injury to that area.

Findings

- All Lumber tests were normal, with full ROM,
- All neurological testing was also negative.
- AROM hip – Adduction caused discomfort in the groin area 2/6
- PROM hip- Abduction caused discomfort in the groin area to the medial knee. 2/6
- RROM hip Adduction caused pain in the groin area 3/6
- Hypertonic adductors
- Palpation, tender along the adductor muscle group to the attachment.

Goals

Reduce acute symptoms, Restore normal ROM. Educate in flexibility and strength programme and to return to normal daily living pain free.

Treatment and response

Treatment one

Tender points were found at the muscle origin from the inferior pubic ramus and down the length of the muscle. A Strain counter strain technique was used. Patient supine hip flexed slightly and

adducted, the pain eased after approximately 90 seconds, from a 2-3 out of six, soft tissue work was done to the medial hamstring also. Reassessment showed improvement in all ROM pain had decreased by one level. He was advised to rest from horse riding.

Treatment two (4 days later)

Patient reports that the pain has stayed at the decreased level, 2/6 on assessment

- AROM hip – Adduction caused discomfort in the groin area 1/6
- PROM hip- Abduction caused discomfort in the groin area to the medial knee. 1/6
- RROM hip Adduction caused pain in the groin area 2/6
- Hypertonic adductors
- Palpation, tender along the adductor muscle group to the attachment.

Treatment is the same as the first treatment, Mobilisation to the hip and sacral region was also performed. SCS technique to the right Psoas. Reassessment, Full hip Rom was restored with no pain. Tenderness along muscle had decreased

Treatment three (7 days later)

The patient reported that the pain was totally decreased, he returned to his horse riding with no ill effects afterwards. On assessment all testing was negative. Soft tissue work was done to the adductors, medial hamstrings, ITB, Hip mobs and Sacral mobs. A home care plan was put in place, firstly stretching the ITB and some strength for the Adductors,

Treatment four (10 days)

The patient had resumed full activity with no ill effects, no positive findings were noted. ITB had lengthened, taking the constant stretch off the adductors that was coming due to horse riding, and the adductors had strengthened up, making then better able to cope with the stress of horse riding.

Conclusion

The adductor muscle group had become dysfunctional from the constant stretch on then during horse riding, causing small zones of tense tender oedematous muscle and fascial tissue. Strain counterstrain combated the acute pain that the client was feeling, meaning that I could carry out more treatment on mobilizing the hips and sacrum, returning the joint to normal ROM. The pain was too acute to use myofascial techniques, and the pain eased quicker using SCS, while using less effort and less invasive for the patient.